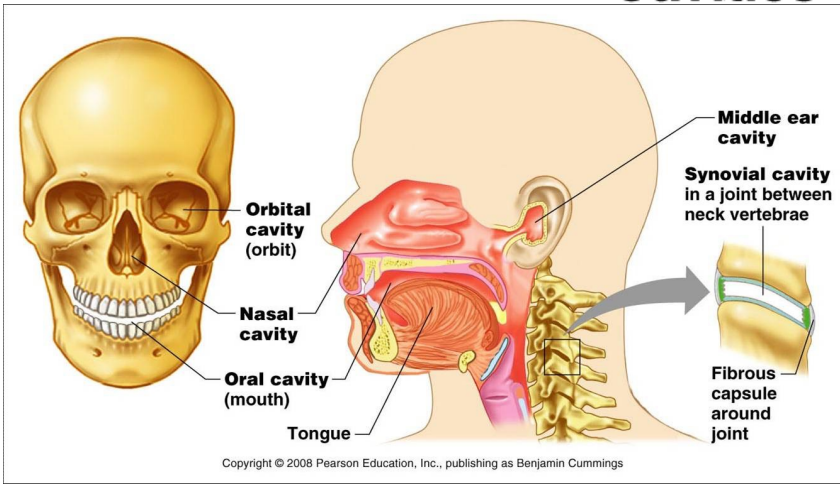
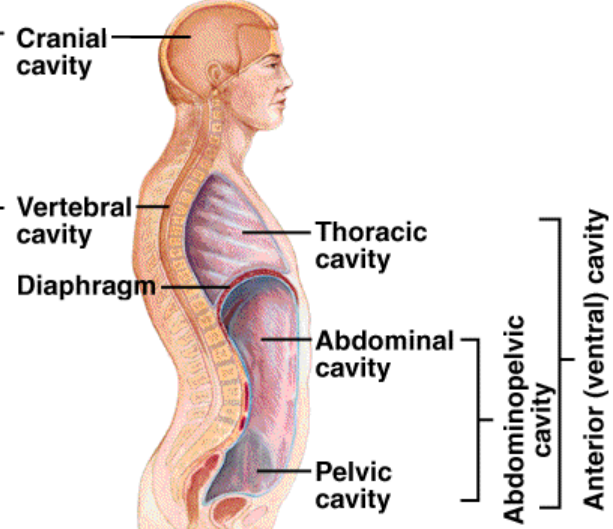


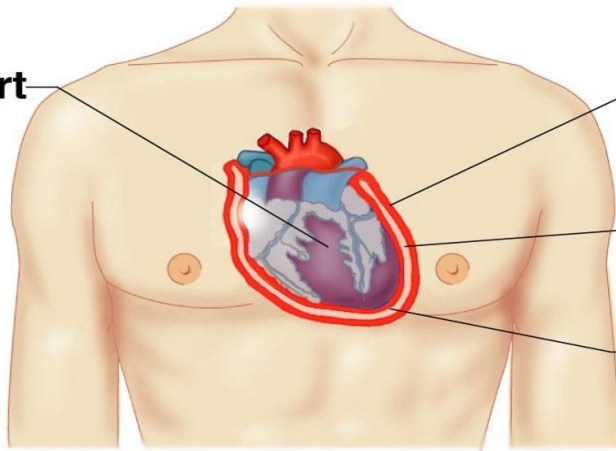
# Body Cavities



Posterior (dorsal) cavity



Heart



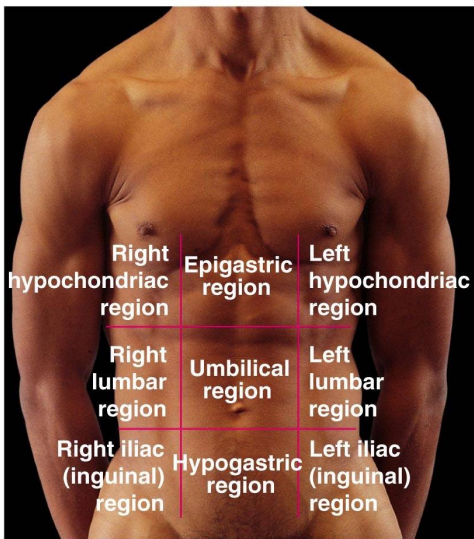
Parietal pericardium

Pericardial cavity with serous fluid

Visceral pericardium

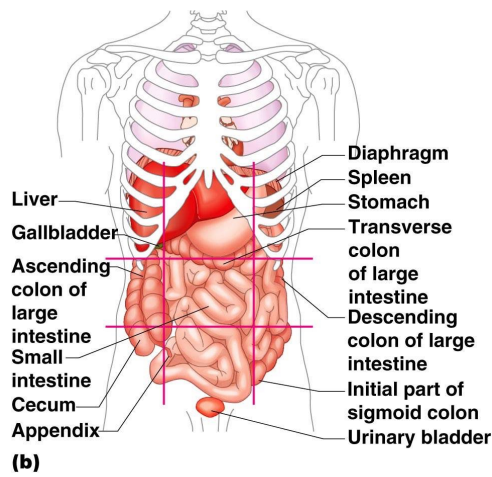
(b)

Copyright © 2008 Pearson Education, Inc., publishing as Benjamin Cummings



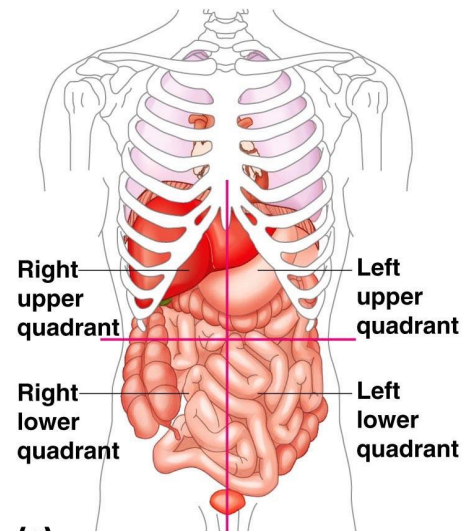
(a)

Copyright © 2008 Pearson Education, Inc., publishing as Benjamin Cummings



(b)

Copyright © 2008 Pearson Education, Inc., publishing as Benjamin Cummings



(c)

Copyright © 2008 Pearson Education, Inc., publishing as Benjamin Cummings